UNI FR

UNIVERSITÉ DE FRIBOURG
UNIVERSITÄT FREIBURG

Bern Hip Symposium, Vorkurs, 2020

Bloody Hell –

Wie funktioniert die Durchblutung der Hüfte?

Moritz Tannast

Professor, Chefarzt transversal, Klinik für Orthopädische Chirurgie & Traumatologie

HFR Kantonsspital Fribourg, Universität Fribourg, Schweiz

Einleitung (1)

- **Wichtigste Information** in der Gelenkserhaltenden Hüftchirurgie

- Die Kenntnis des genauen topographischen Verlaufes der Femurkopfdurchblutung war die Grundlage für
  - die Technik der chirurgischen Hüftluxation ohne Risiko einer avaskulären Nekrose
  - die Entdeckung des femoroazetabulären Impingements

Sobotta

Internet

Einleitung (2)

Der **R. profundus der A. circumflexa femoris medialis** ist hauptverantwortlich und suffizient für die Durchblutung des Femurkopfes.

- Die arterielle Versorgung
  - entspringt anterior,
  - verläuft zwischen Becken und Femur,
  - versorgt den Femurkopf von posterior

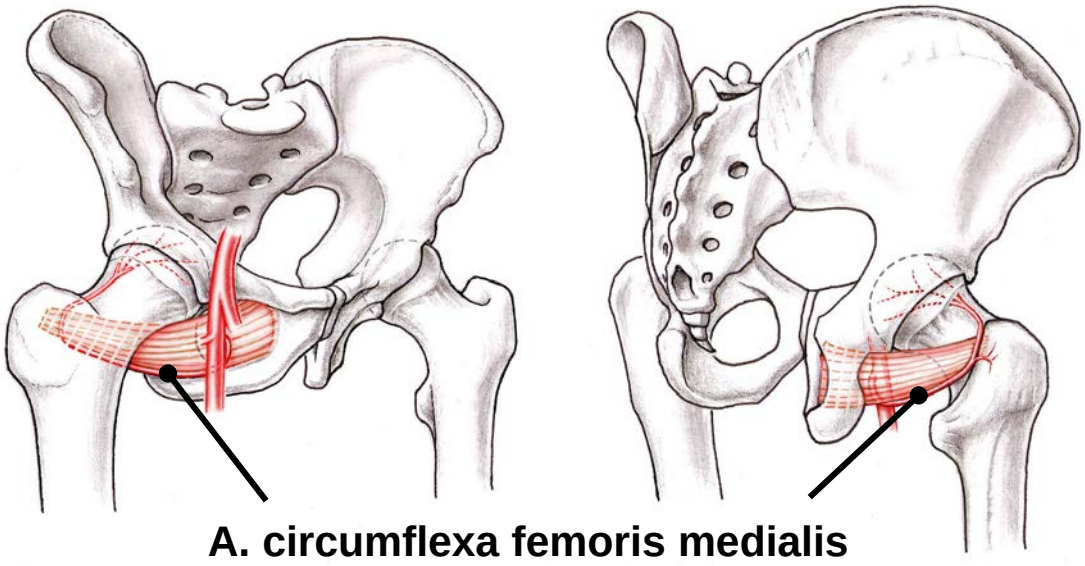

A. circumflexa femoris medialis

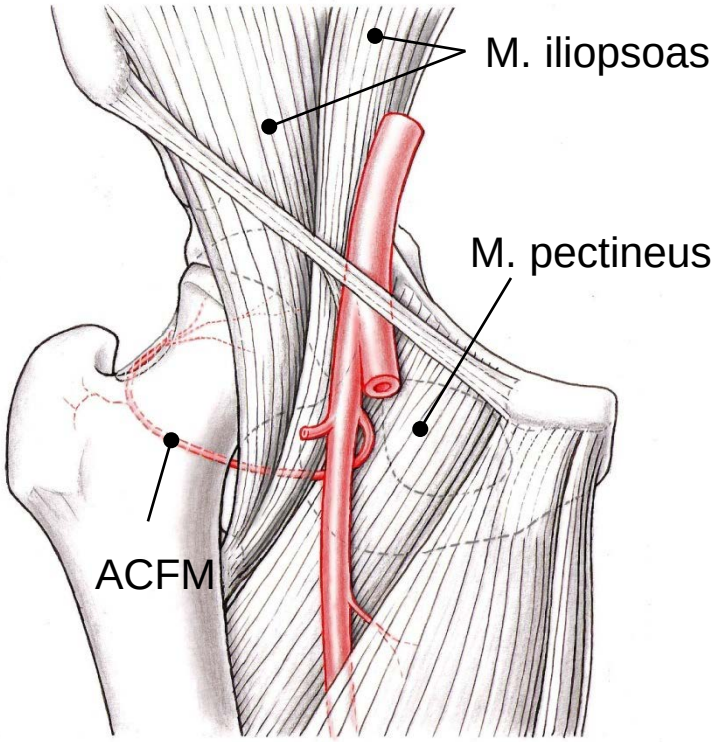

- Ursprung: A. profunda femoris
- Zwischen M. iliopsoas und M. pectineus

Gautier et al, JBJS Br. ***2000*** *82(5):679-83.*

Courtesy
M. Kalhor

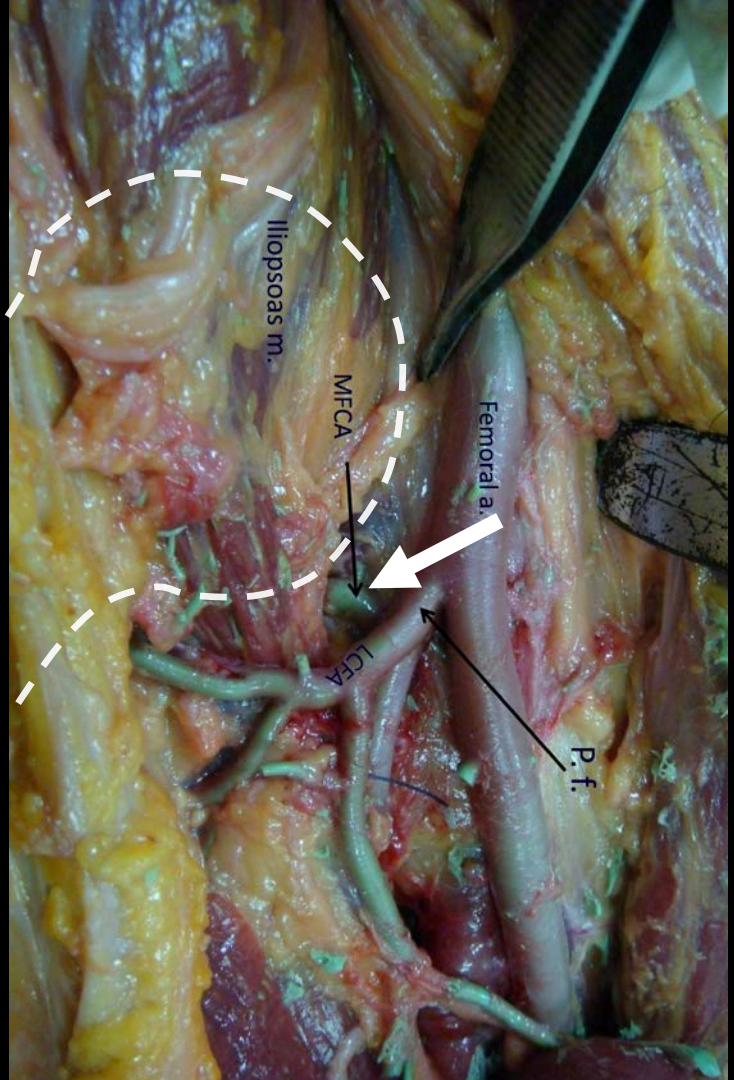

A. circumflexa femoris medialis

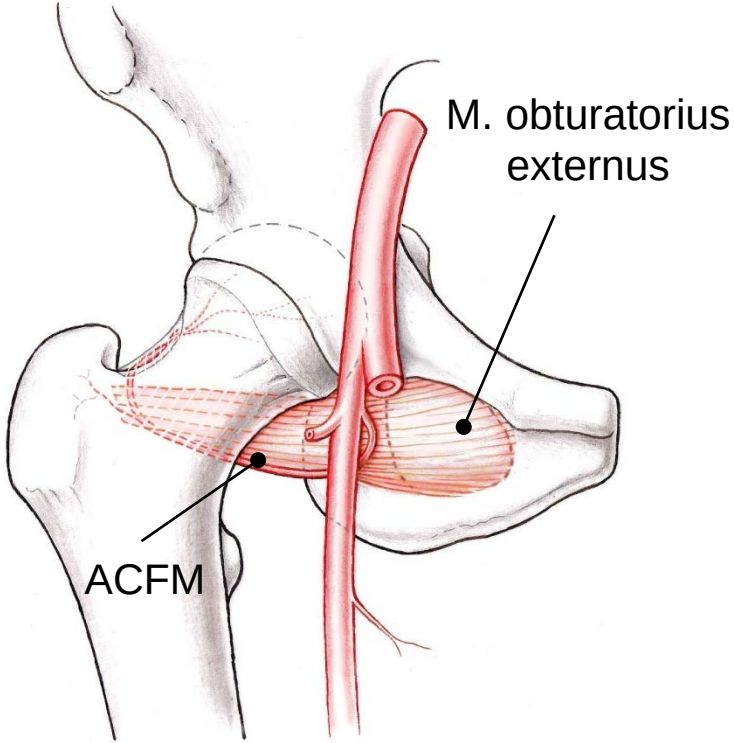

- Ursprung: A. profunda femoris
- Zwischen M. iliopsoas und M. pectineus
- Unterrand M. obturatorius externus

Gautier et al, JBJS Br. ***2000*** *82(5):679-83.*

Courtesy
M. Kalhor

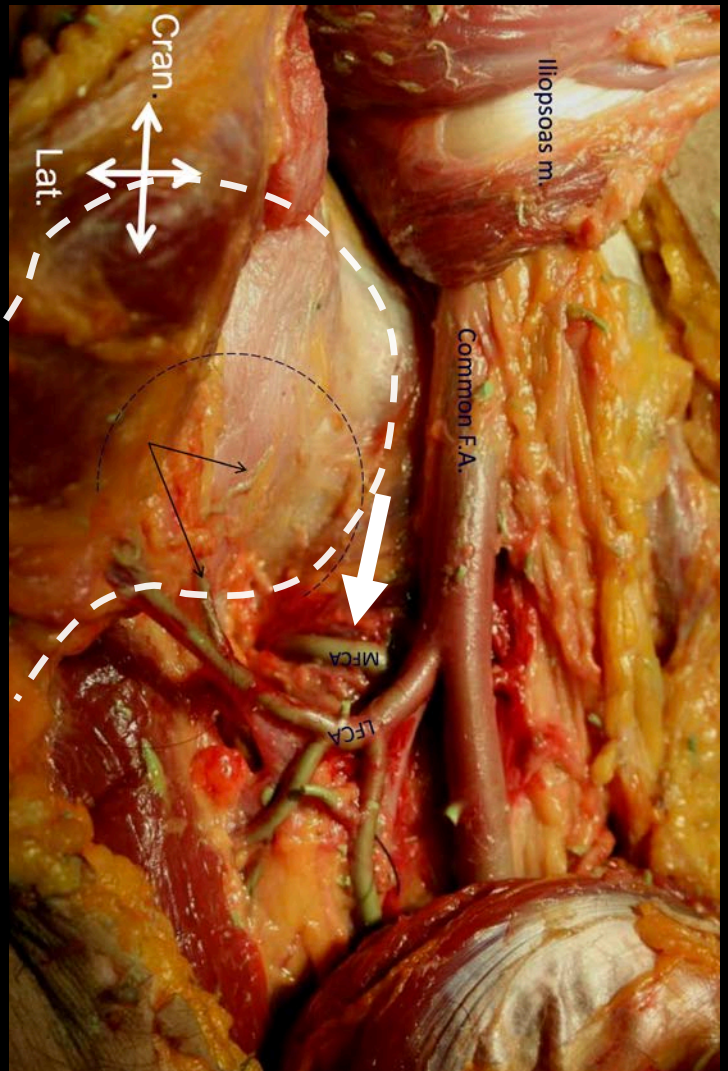

A. circumflexa femoris medialis

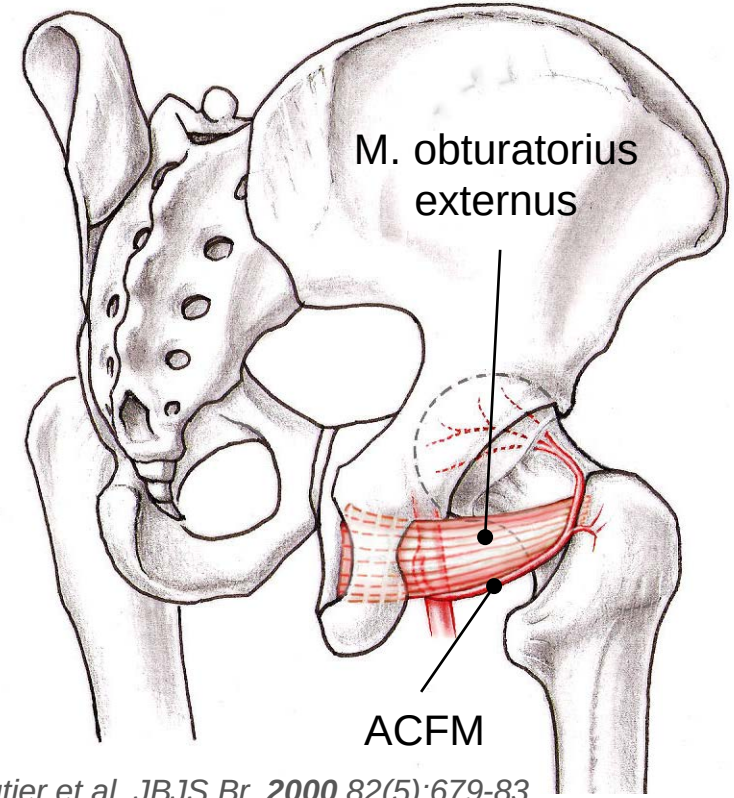

Gautier et al, JBJS Br. ***2000*** *82(5):679-83.*

- Ursprung: A. profunda femoris
- Zwischen M. iliopsoas und M. pectineus
- Unterrand M. obturatorius externus
- Nach posterior Richtung Crista intertrochanterica

A. circumflexa femoris medialis

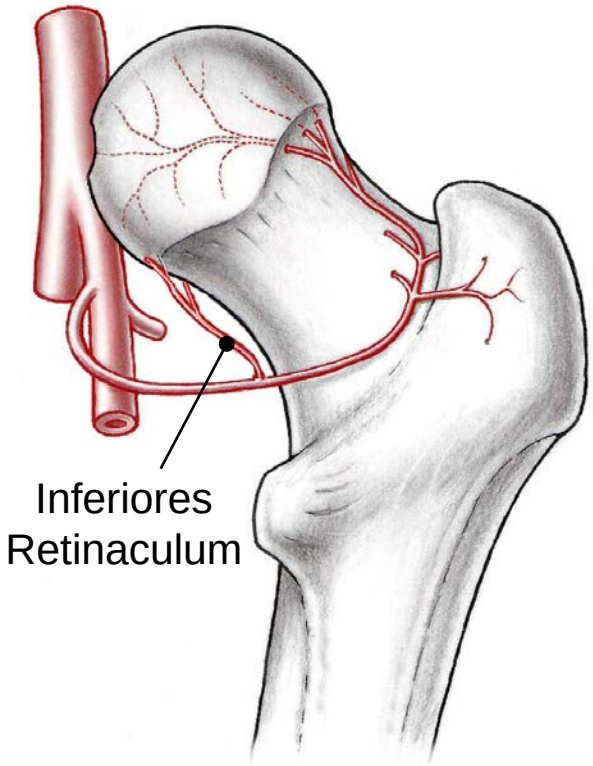

- Ursprung: A. profunda femoris
- Zwischen M. iliopsoas und M. pectineus
- Unterrand M. obturatorius externus
- Nach posterior Richtung Crista intertrochanterica
- Inferiores Retinaculum

Gautier et al, JBJS Br. ***2000*** *82(5):679-83.*

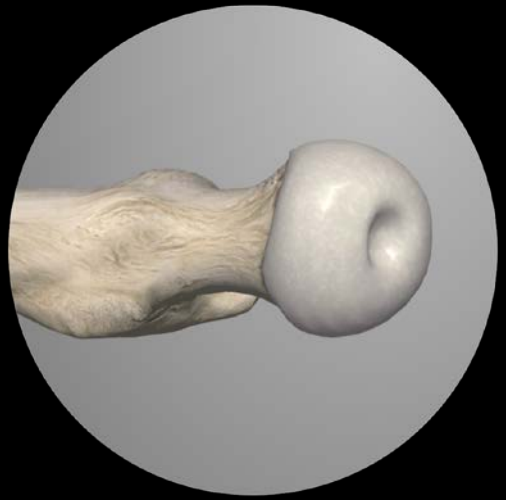

Courtesy
M. Kalhor

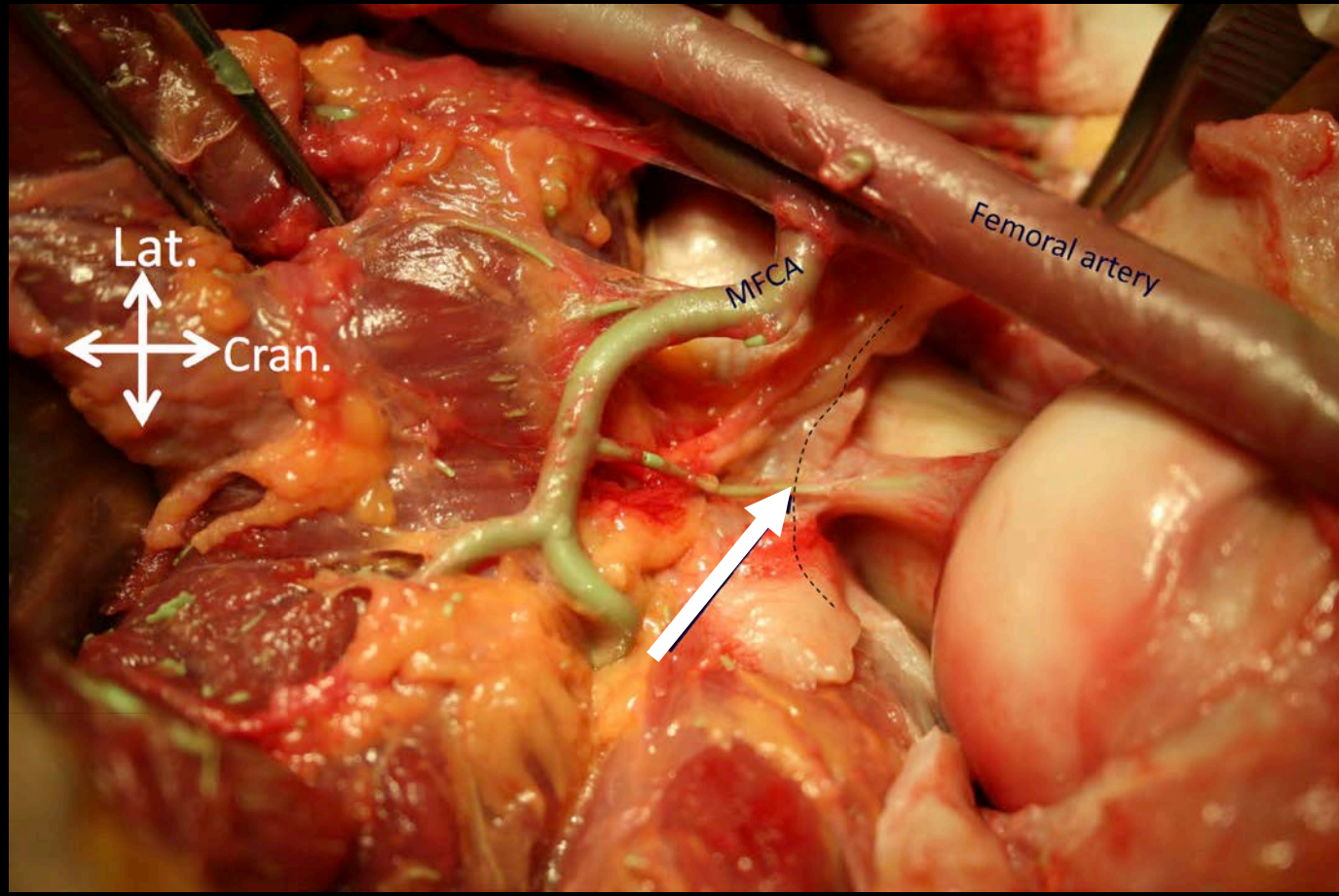

A. circumflexa femoris medialis

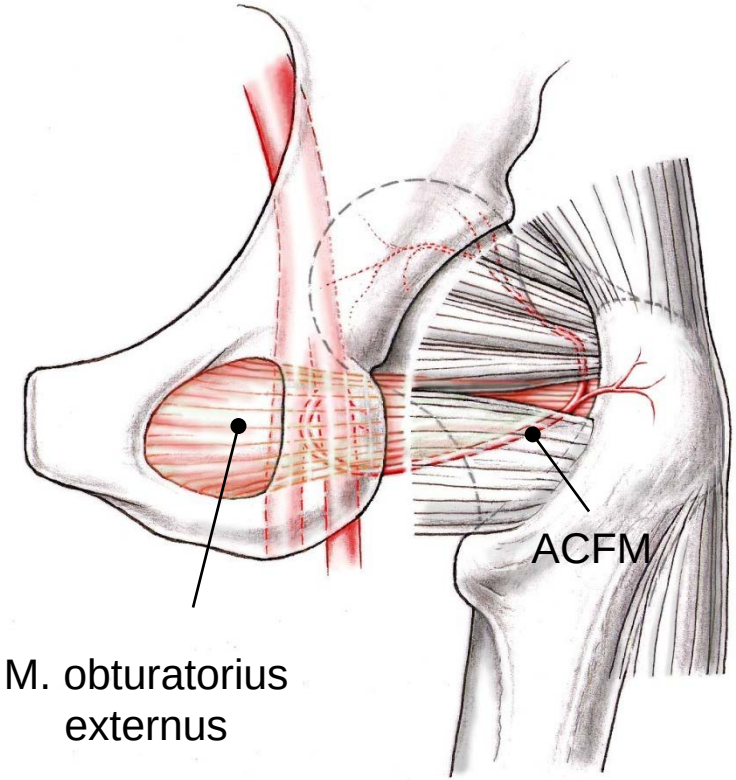

- Ursprung: A. profunda femoris
- Zwischen M. iliopsoas und M. pectineus
- Unterrand M. obturatorius externus
- Nach posterior Richtung Crista intertrochanterica
- Inferiores Retinaculum
- Überkreuzung M. obturatorius externus

Gautier et al, JBJS Br. ***2000*** *82(5):679-83.*

Courtesy
M. Kalhor

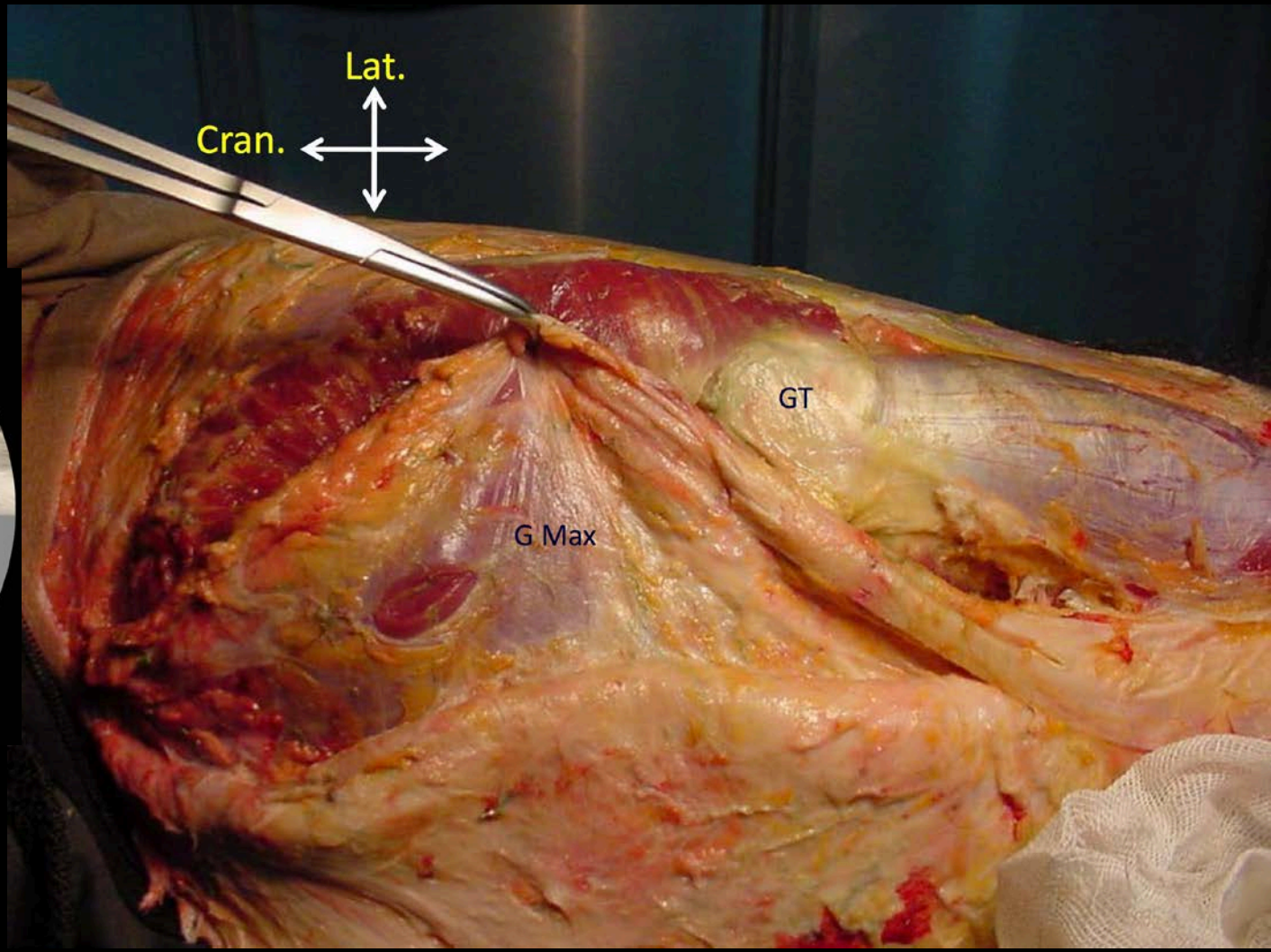

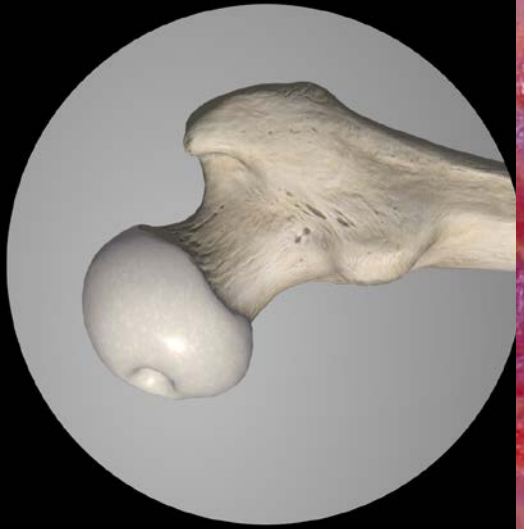

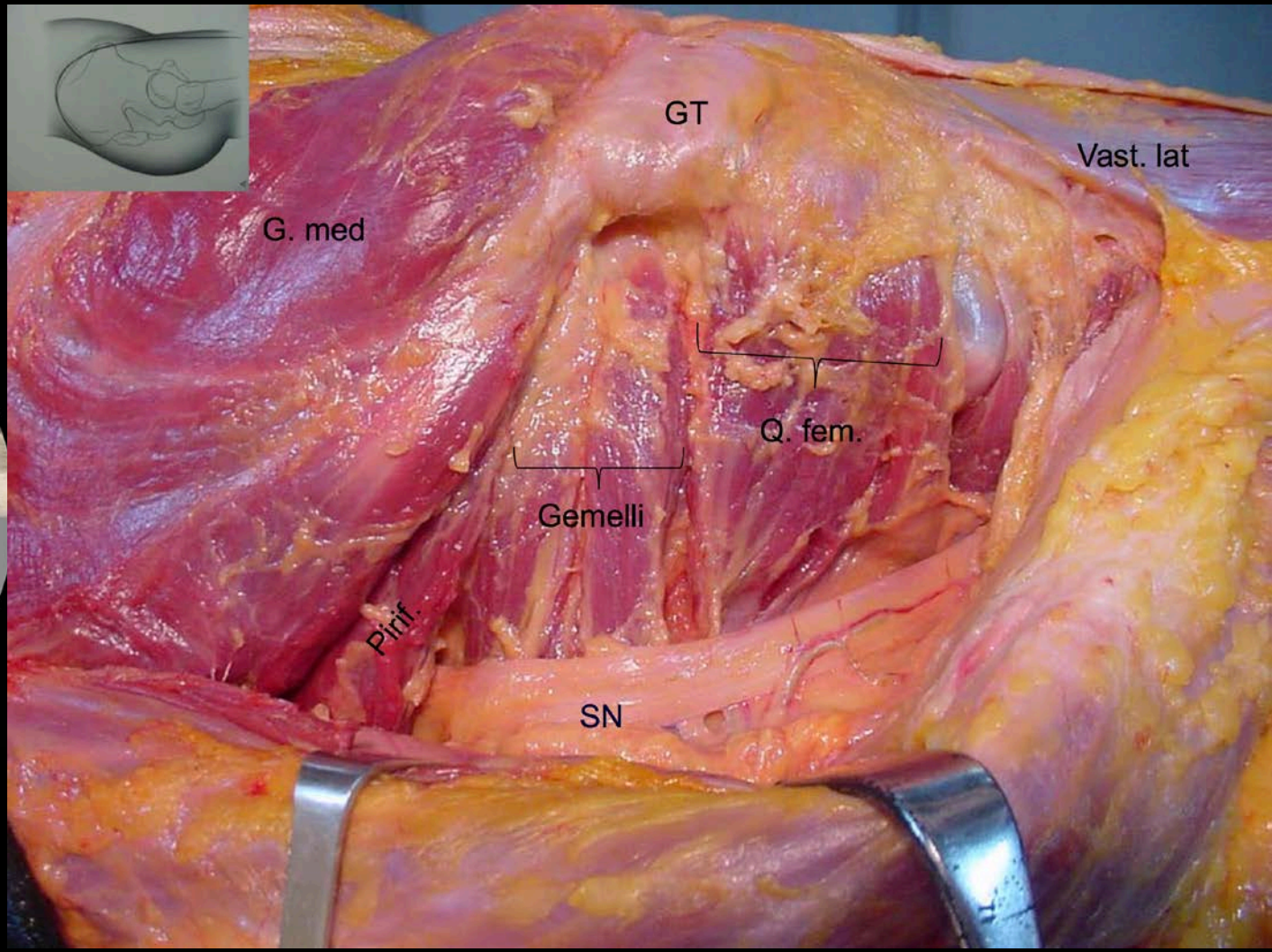

Courtesy
M. Kalhor

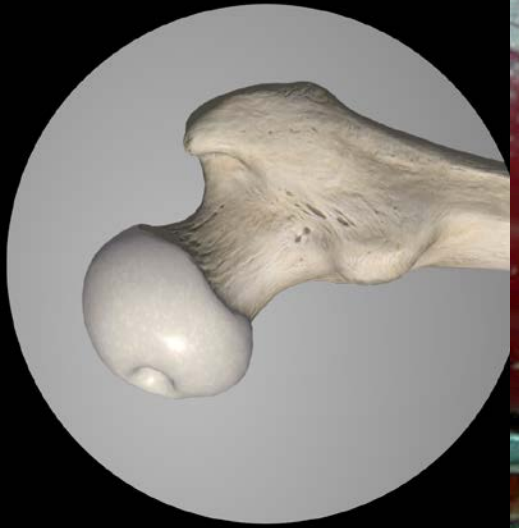

Courtesy
M. Kalhor

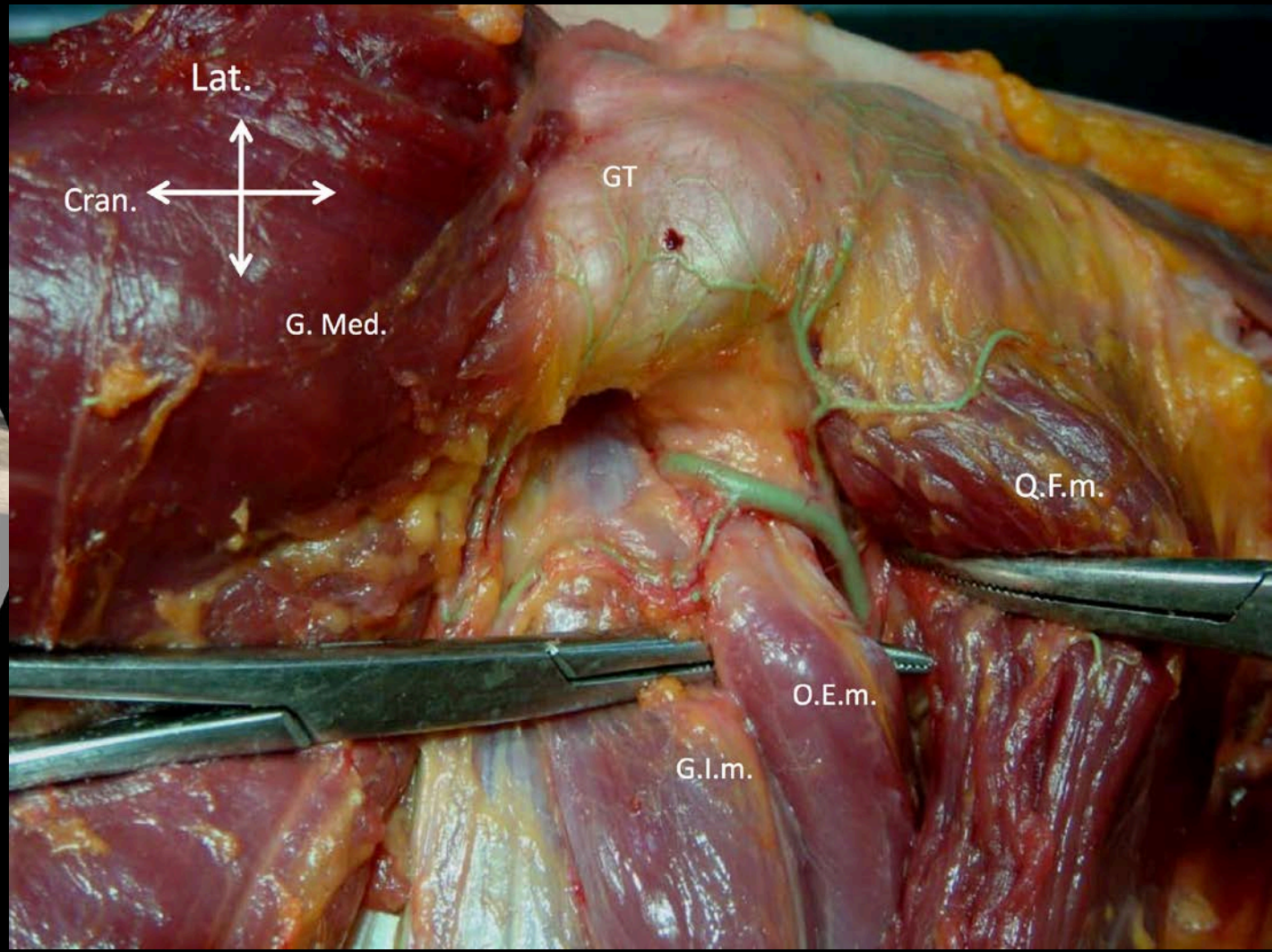

A. circumflexa femoris medialis

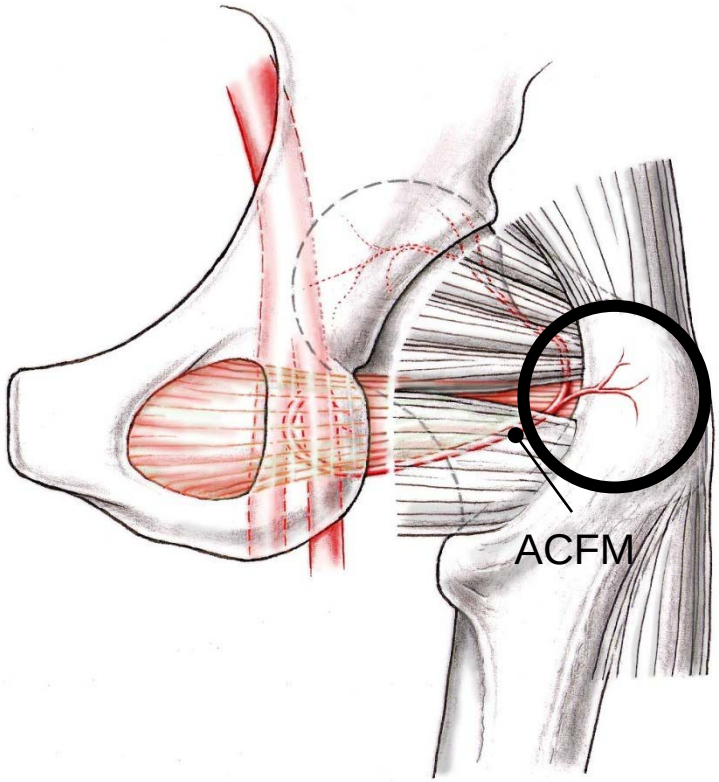

- Ursprung: A. profunda femoris
- Zwischen M. iliopsoas und M. pectineus
- Unterrand M. obturatorius externus
- Nach posterior Richtung Crista intertrochanterica
- Inferiores Retinaculum
- Überkreuzung M. obturatorius externus
- Trochanteräste

Gautier et al, JBJS Br. ***2000*** *82(5):679-83.*

A. circumflexa femoris medialis

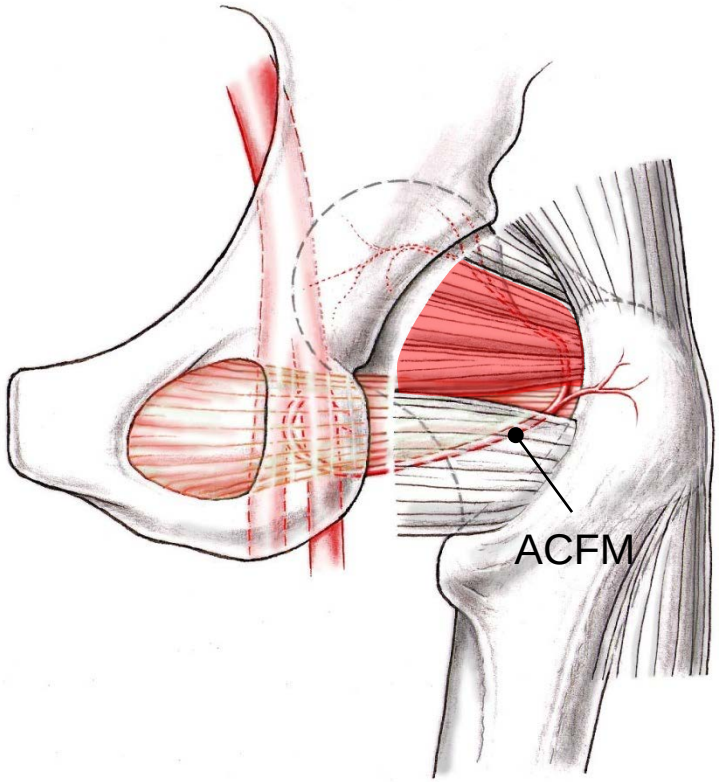

- Ursprung: A. profunda femoris
- Zwischen M. iliopsoas und M. pectineus
- Unterrand M. obturatorius externus
- Nach posterior Richtung Crista intertrochanterica
- Inferiores Retinaculum
- Überkreuzung M. obturatorius externus
- Trochanteräste
- Unterkreuzt M. triceps coxae

Gautier et al, JBJS Br. ***2000*** *82(5):679-83.*

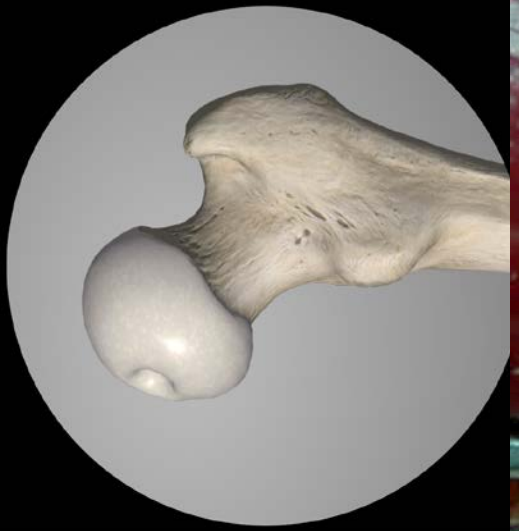

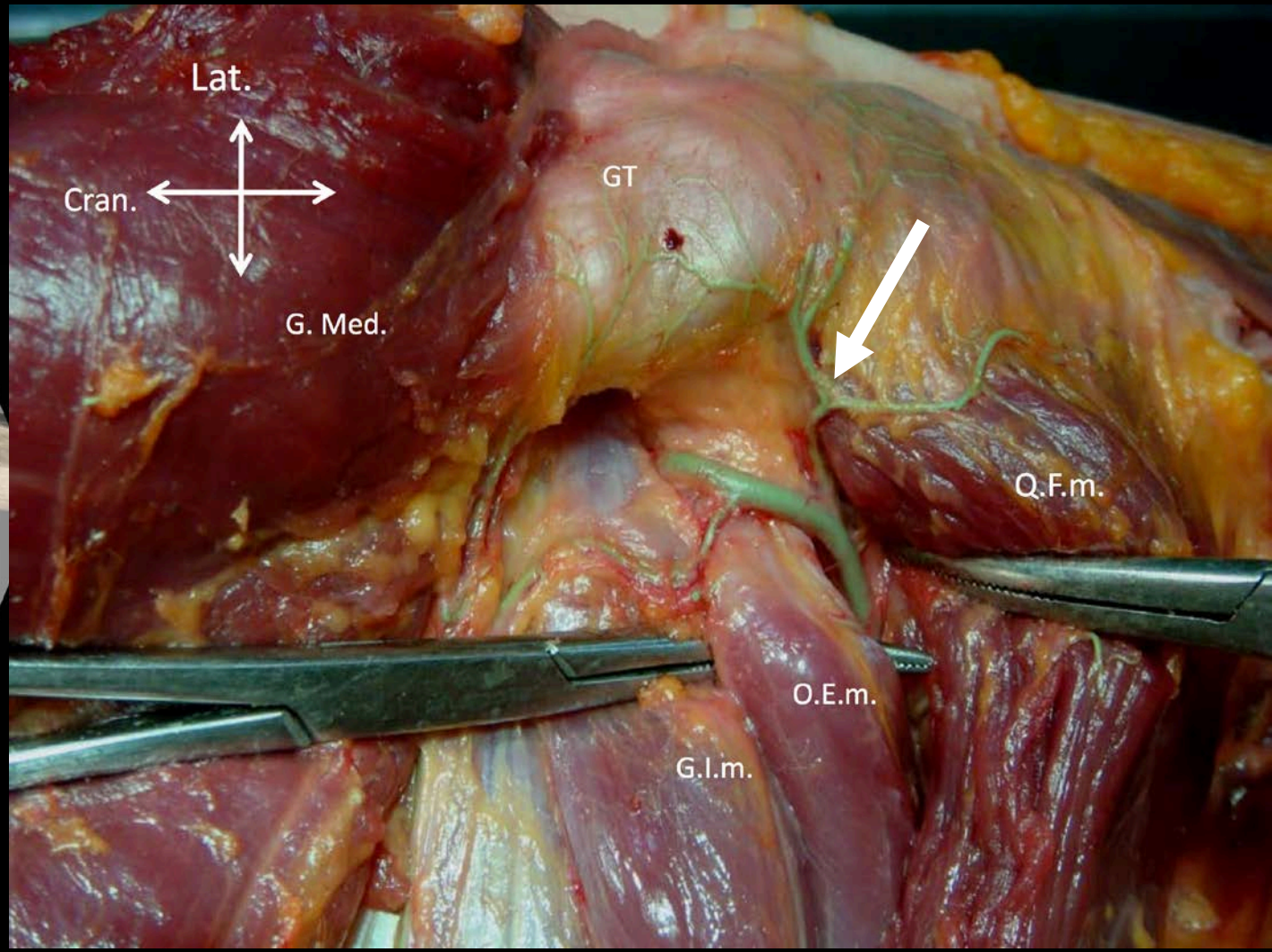

Courtesy
M. Kalhor

A. circumflexa femoris medialis

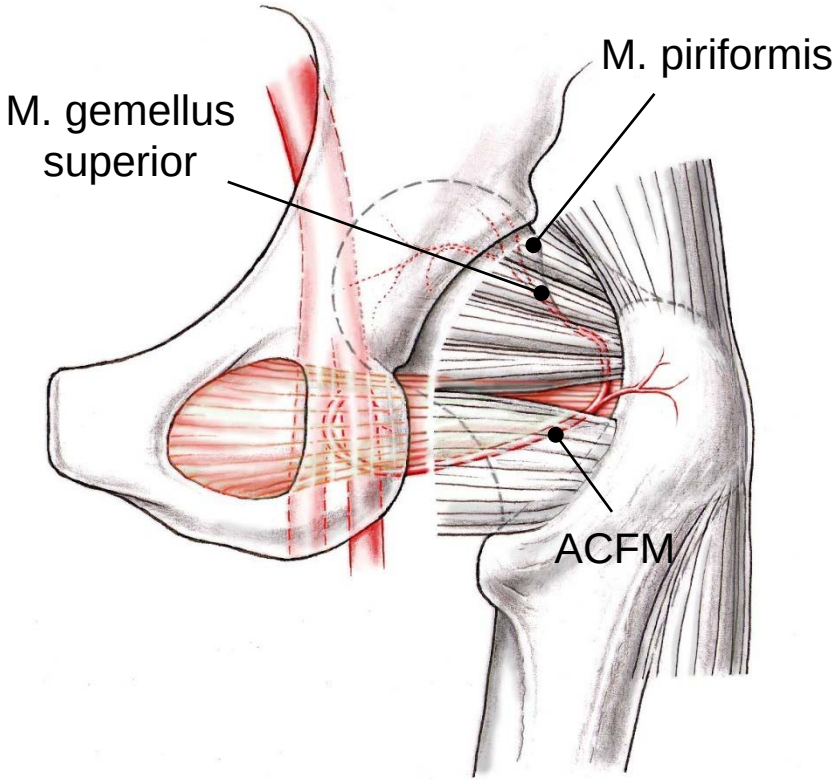

- Ursprung: A. profunda femoris
- Zwischen M. iliopsoas und M. pectineus
- Unterrand M. obturatorius externus
- Nach posterior Richtung Crista intertrochanterica
- Inferiores Retinaculum
- Überkreuzung M. obturatorius externus
- Trochanteräste
- Unterkreuzt M. triceps coxae
- Perforation Gelenkskapsel zwischen Mm. gemellus sup. und M. piriformis

Gautier et al, JBJS Br. ***2000*** *82(5):679-83.*

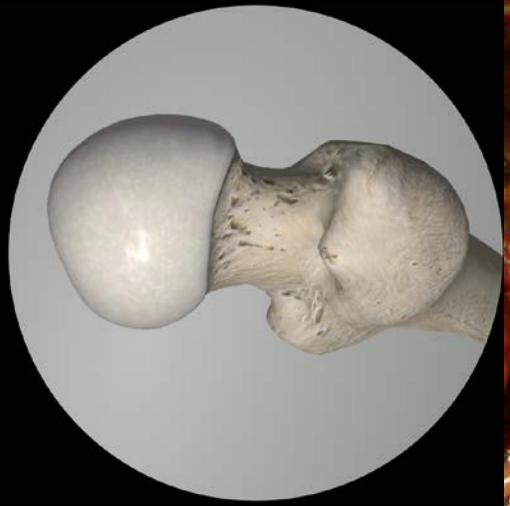

Courtesy
M. Kalhor

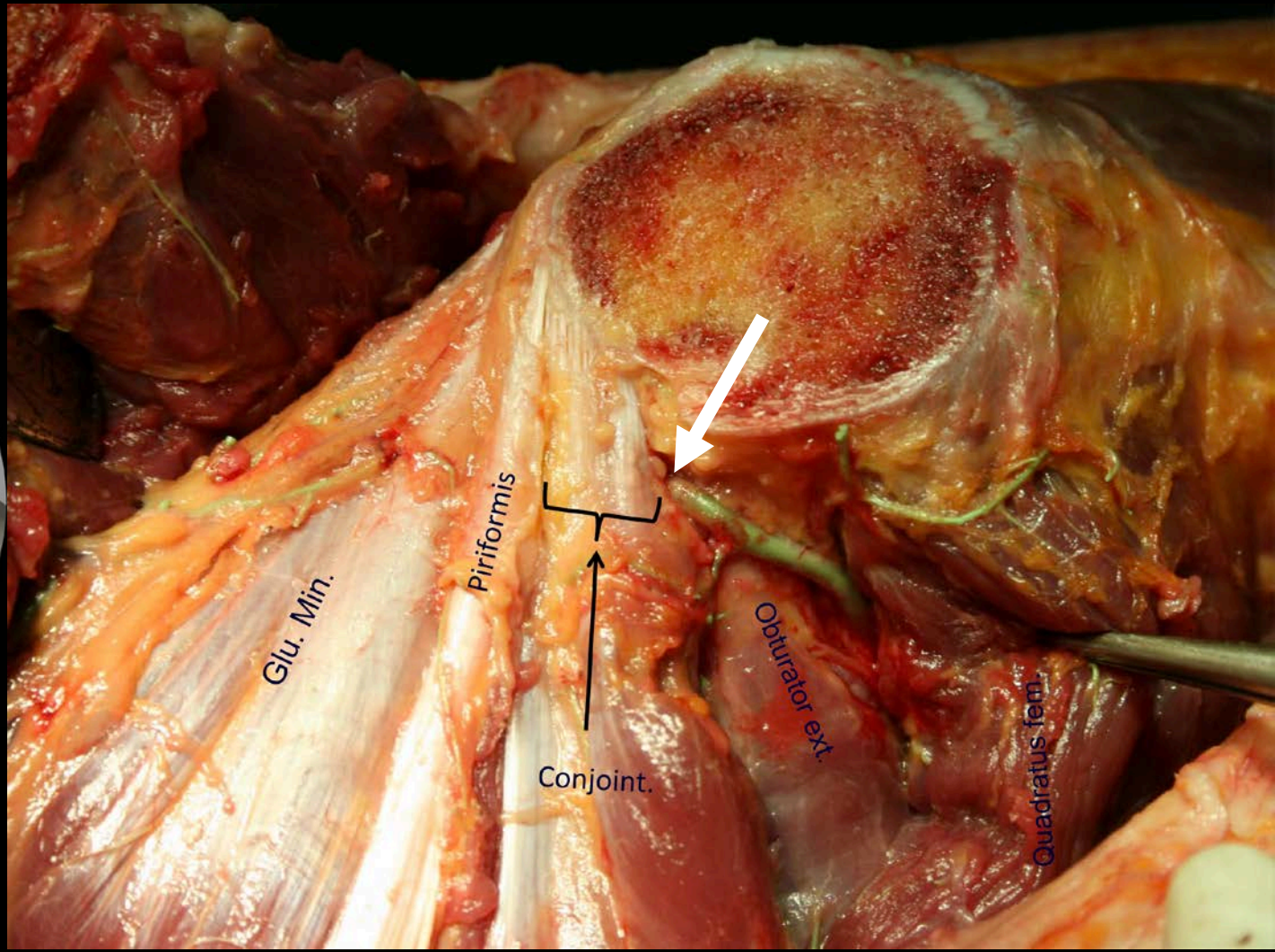

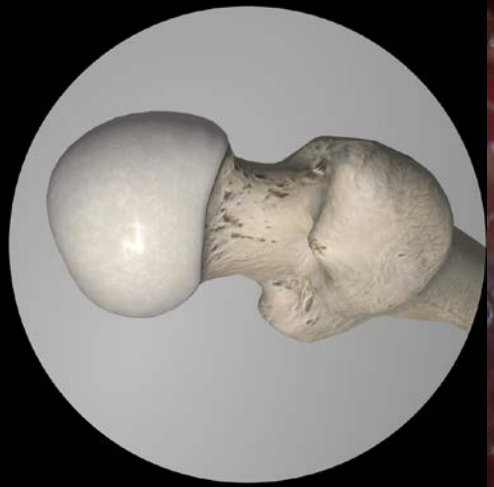

Courtesy
M. Kalhor

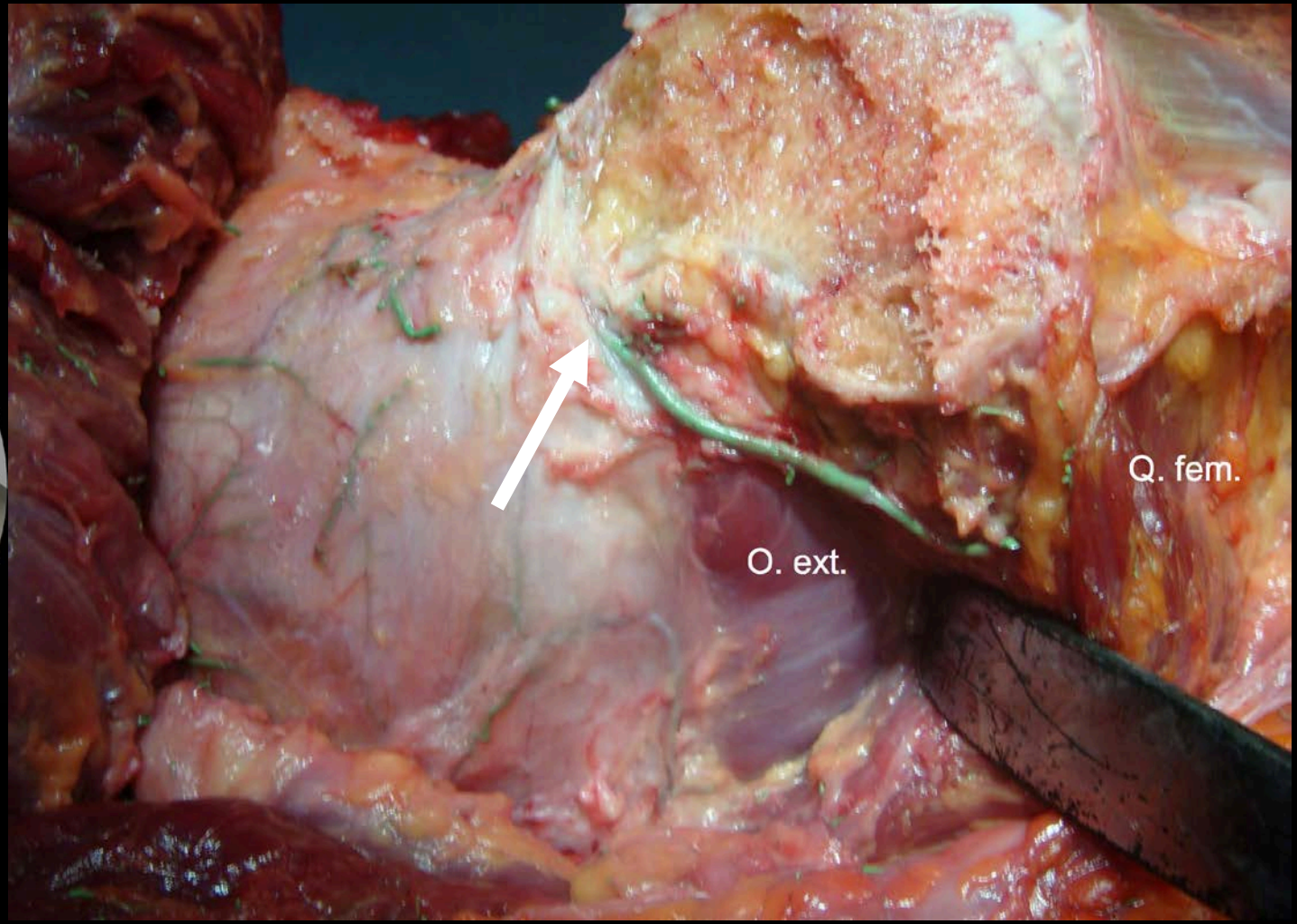

A. circumflexa femoris medialis

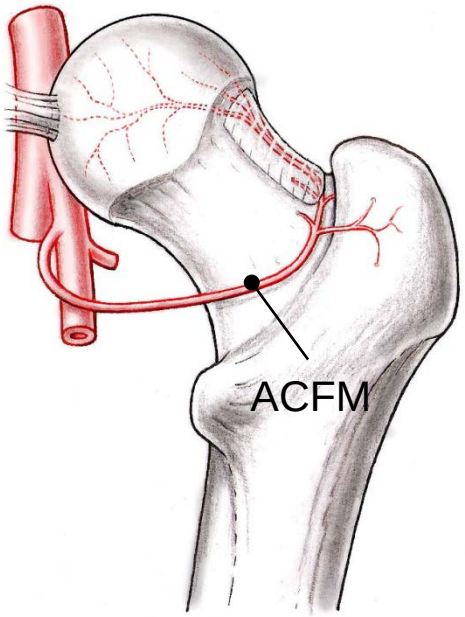

- Ursprung: A. profunda femoris
- Zwischen M. iliopsoas und M. pectineus
- Unterrand M. obturatorius externus
- Nach posterior Richtung Crista intertrochanterica
- Inferiores Retinaculum
- Überkreuzung M. obturatorius externus
- Trochanteräste
- Unterkreuzt M. triceps coxae
- Perforation Gelenkskapsel zwischen Mm. gemellus sup. und M. piriformis
- 4-5 retinakuläre Äste

Gautier et al, JBJS Br. ***2000*** *82(5):679-83.*

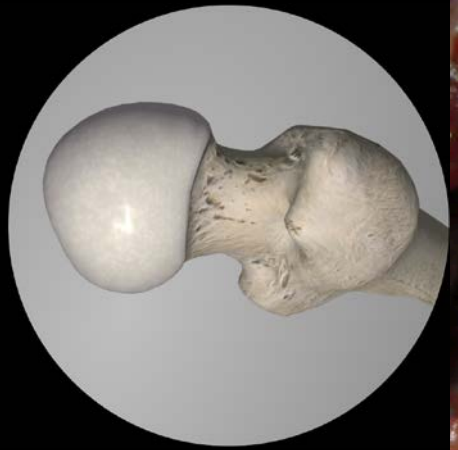

Courtesy
M. Kalhor

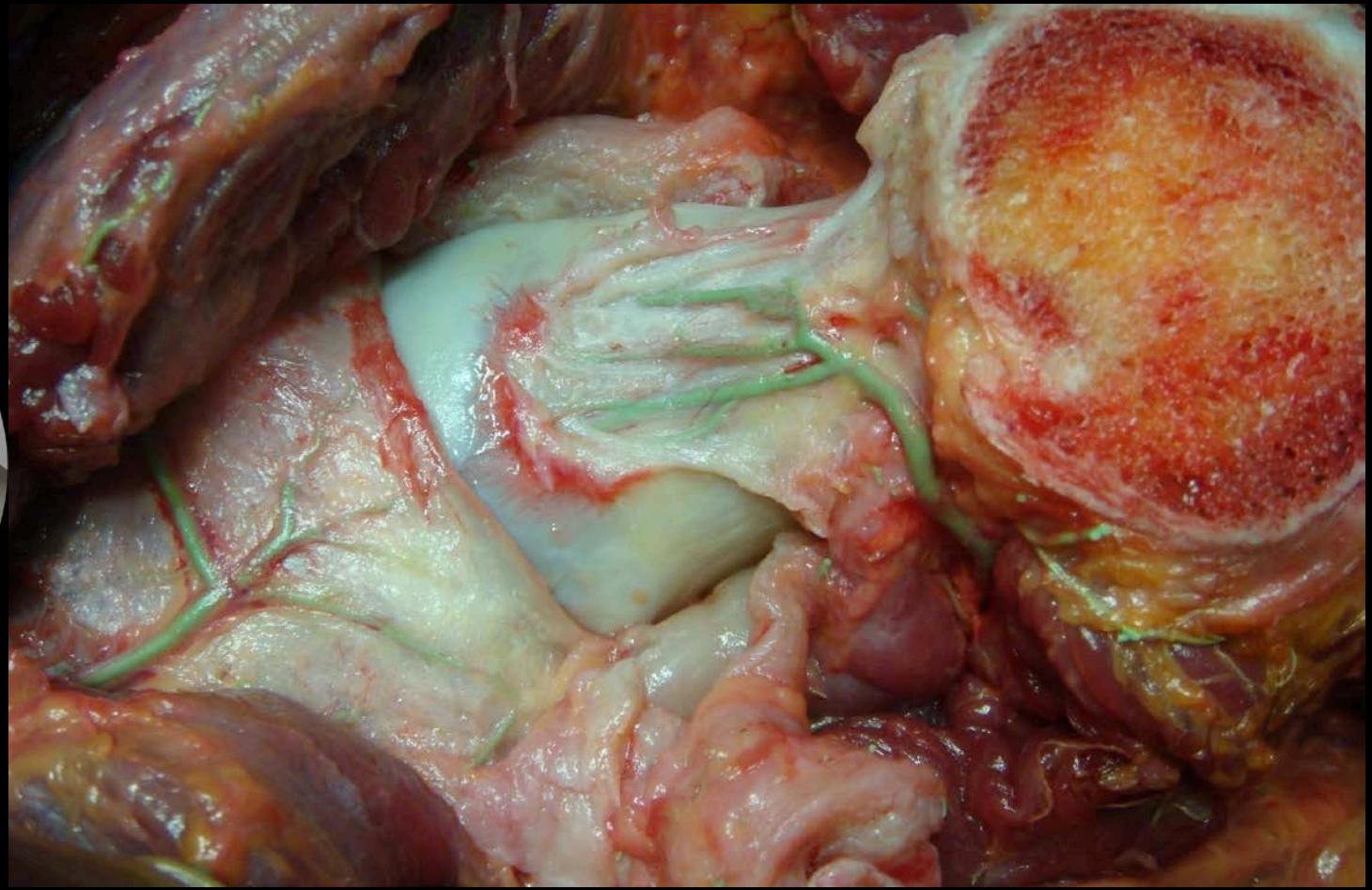

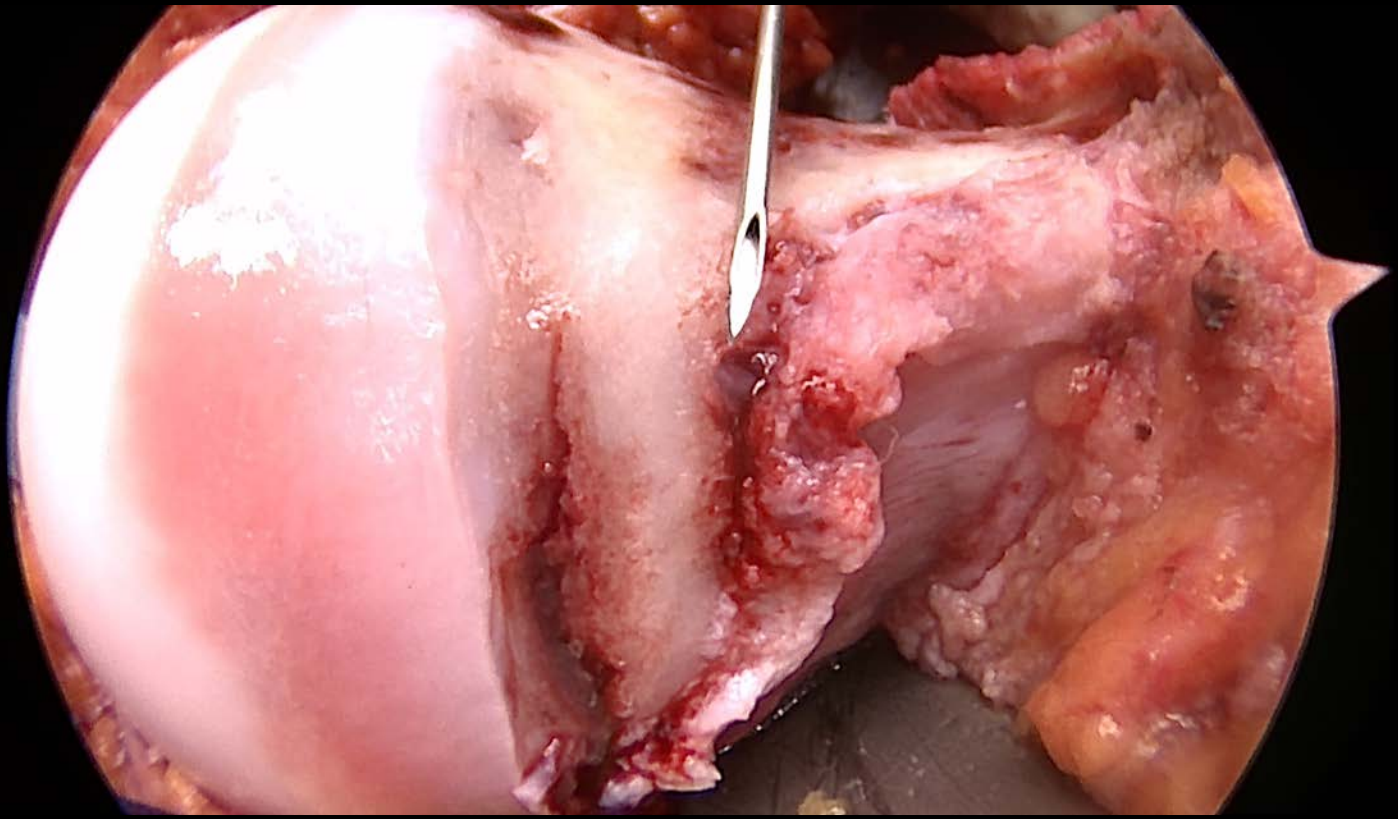

Verteilung der retinakulären Gefässe

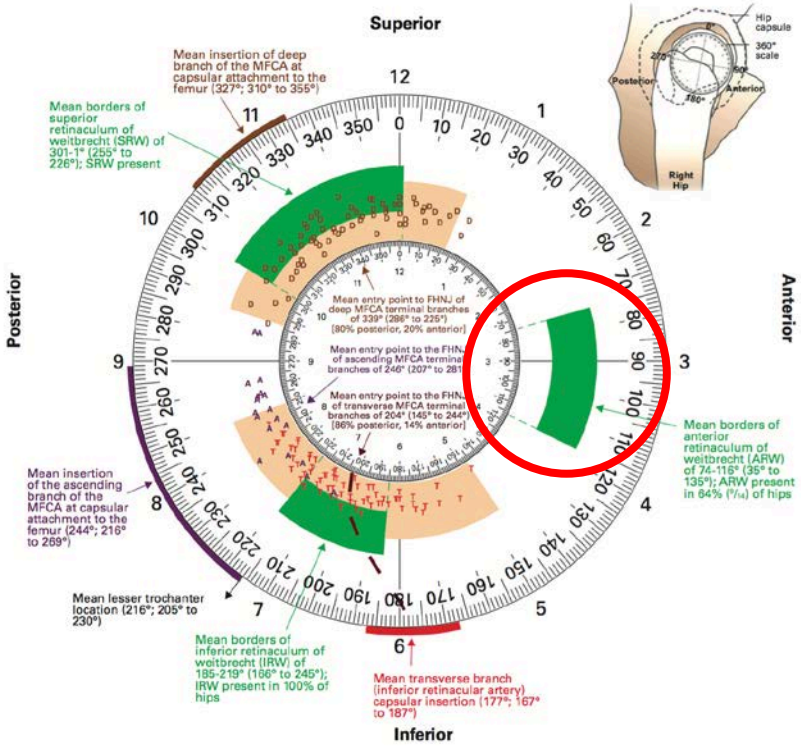

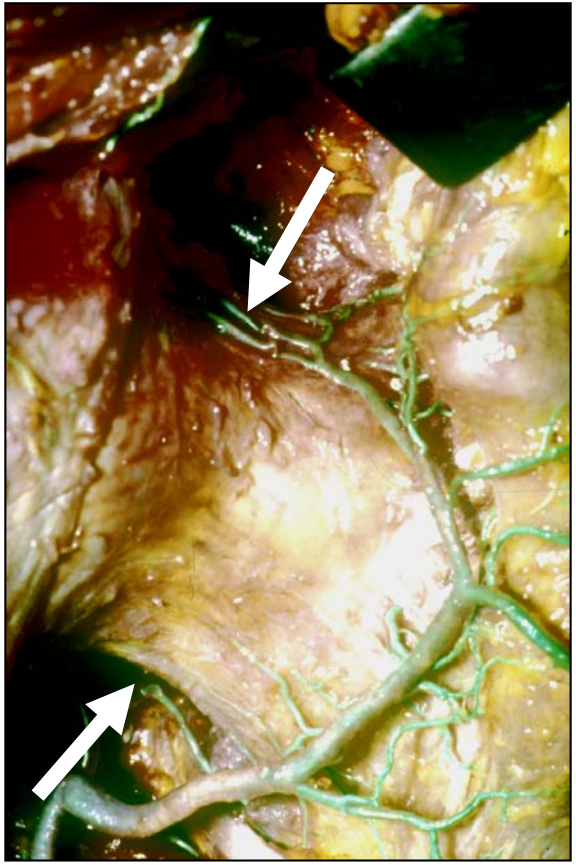

Anteriores Retinaculum (A. circumflexa femoris lateralis)

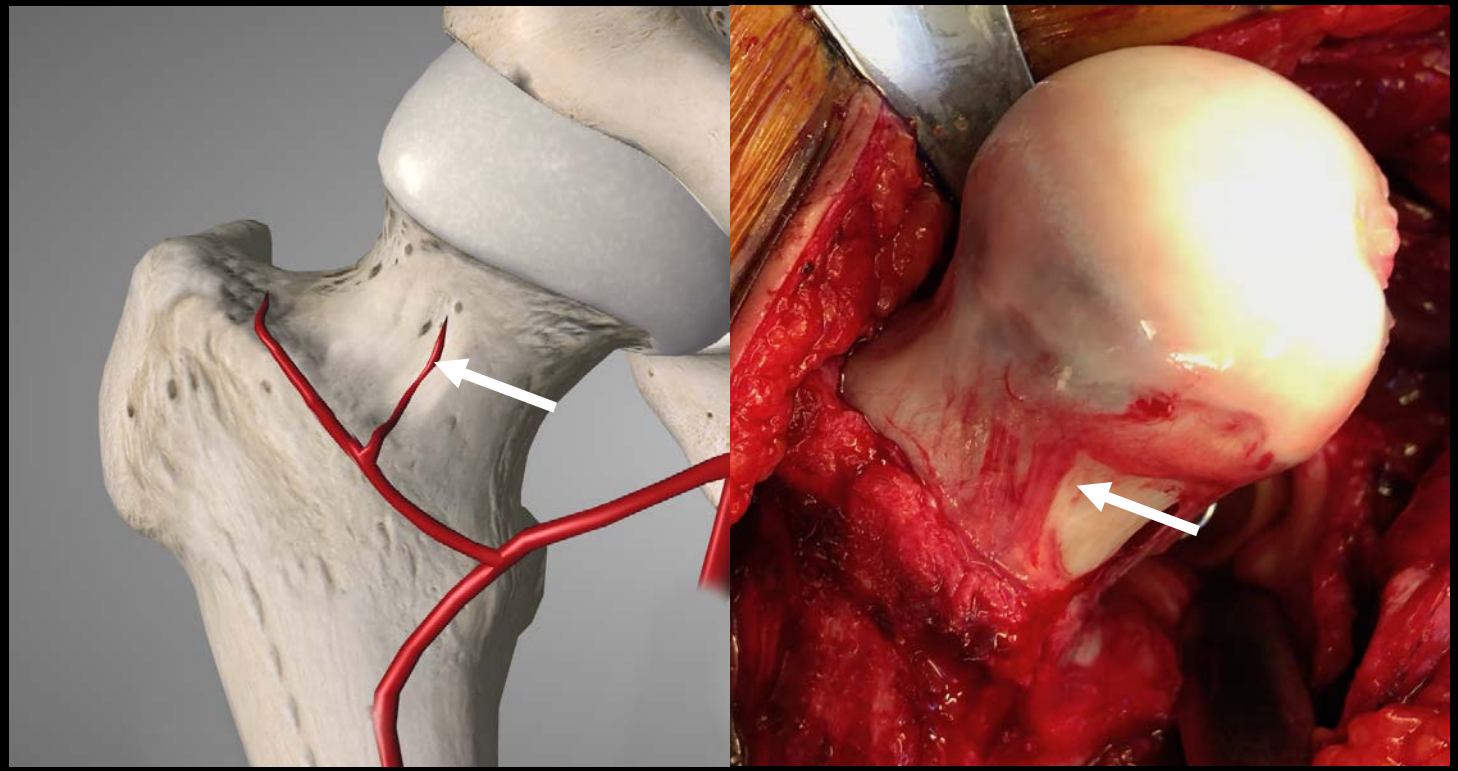

Nicht relevant für die Kopfdurchblutung

Anastomosen und topographischer Verlauf

- Aus der A. glutea inferior entlang des M. piriformis
- In 15% dominantes Gefäss

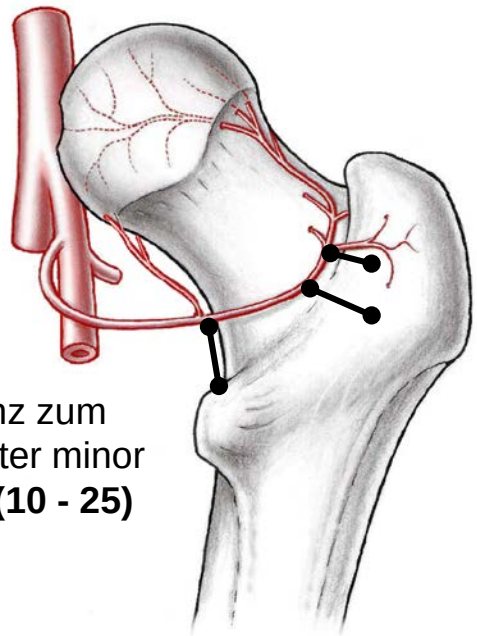

Distanz zur Insertion des M. obturatorius externus
9mm (4 - 16)

Distanz zum Trochanter minor
18mm (10 - 25)

Distanz zur Insertion des M. obturatorius internus
12mm (8 - 18)

Hüftluxation

- Die ACFM ist durch den M. obturator externus geschützt bei der Hüftluxation
- Traumatische Luxation
- Chirurgische Luxation

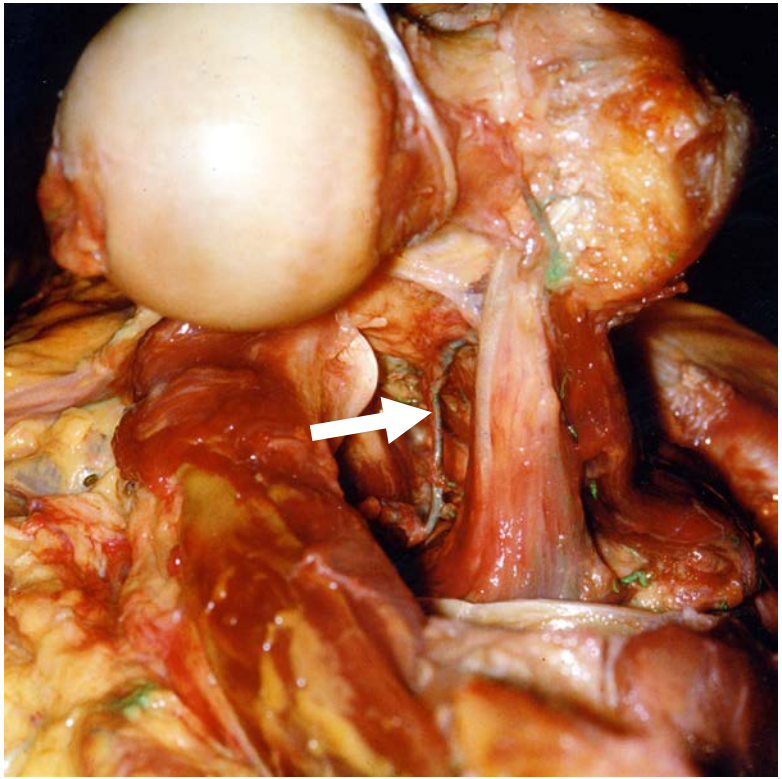

Relevanz der retinakulären Gefässe

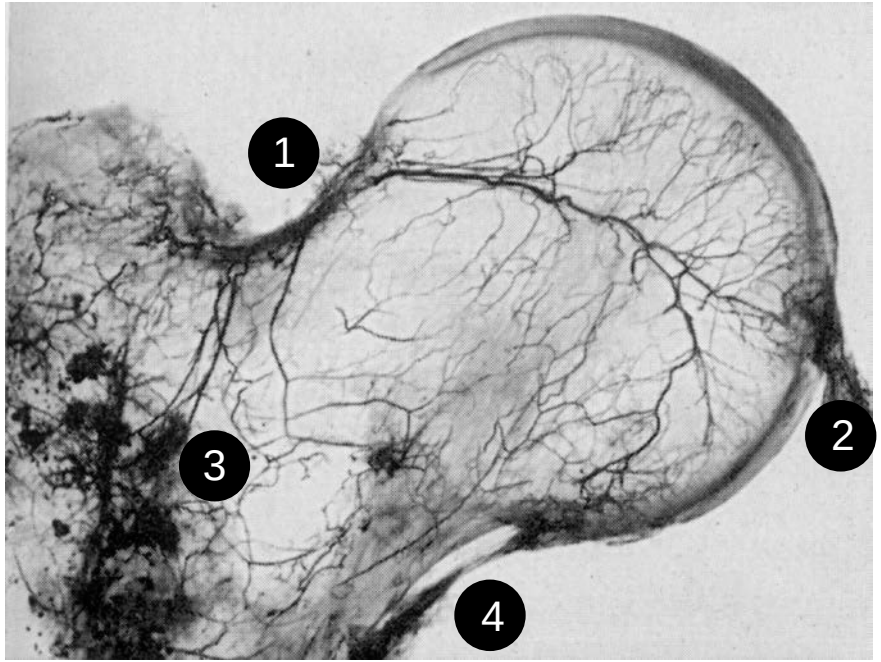

1: Superiores Retinaculum

2: Lig. capitis femoris

3: metaphysär

4: Inferiores Retinaculum

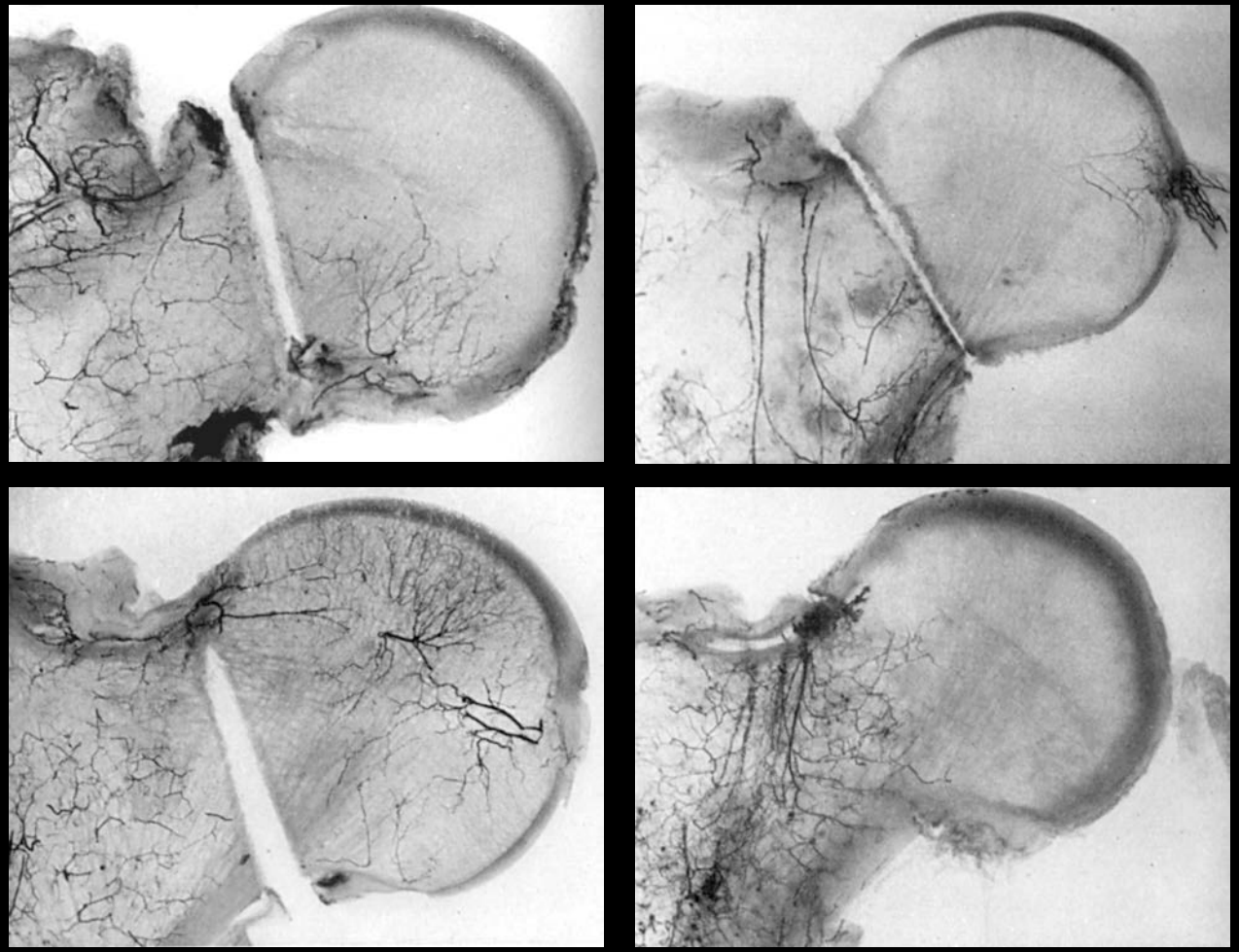

*Sevitt S, Thompson RG. JBJS-B **1965**, 47-B: 560-573*

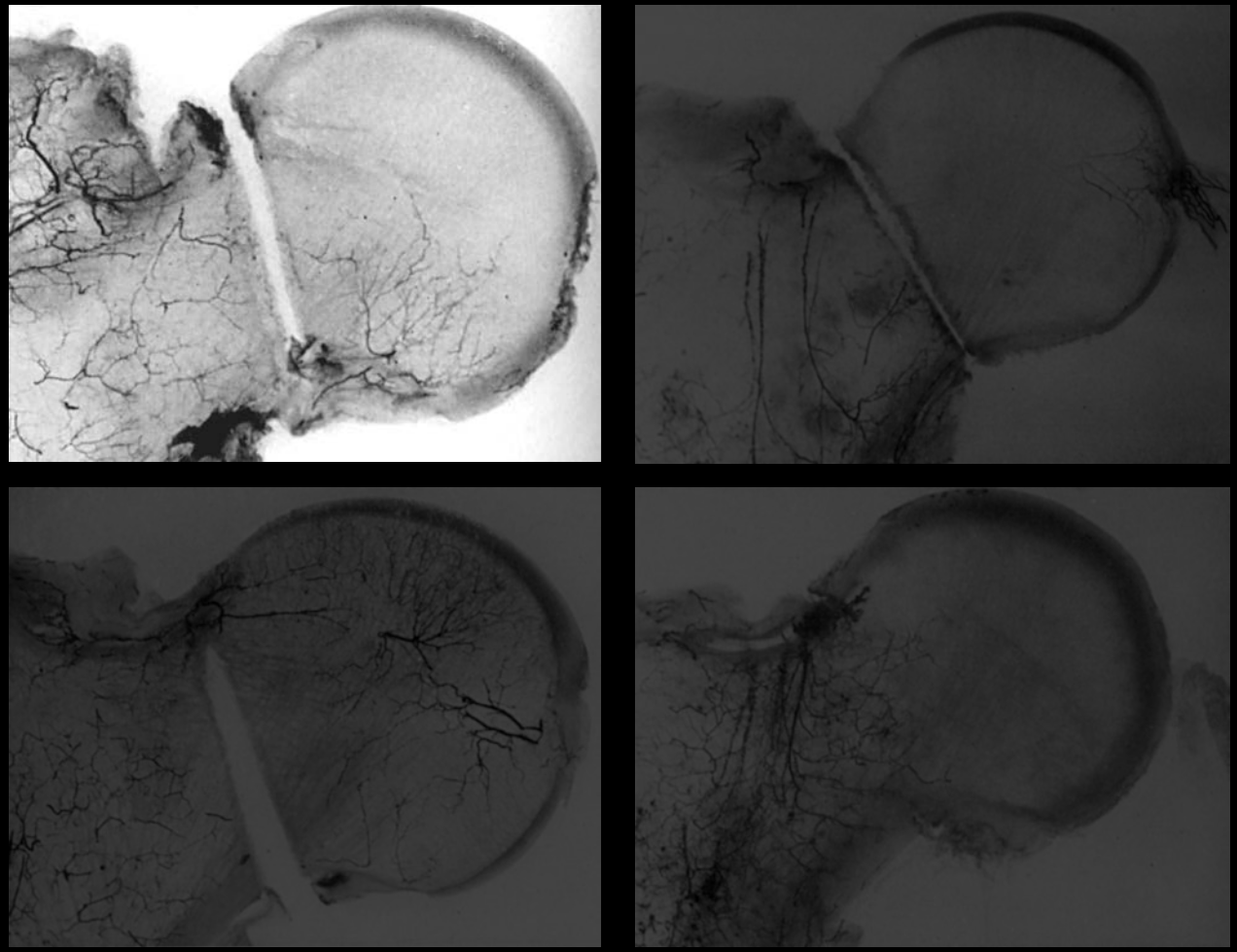

*Sevitt S, Thompson RG. JBJS-B **1965**, 47-B: 560-573*

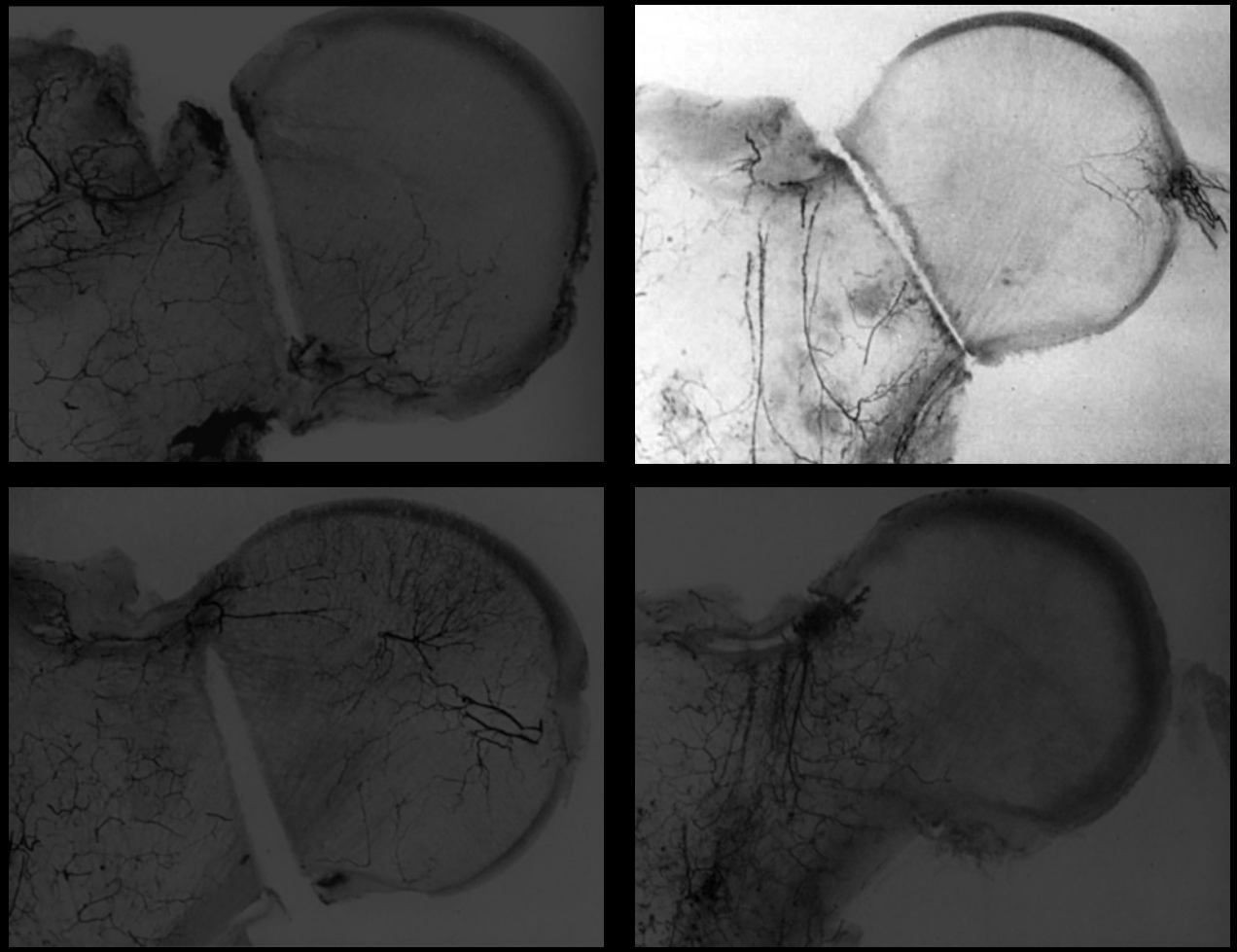

*Sevitt S, Thompson RG. JBJS-B **1965**, 47-B: 560-573*

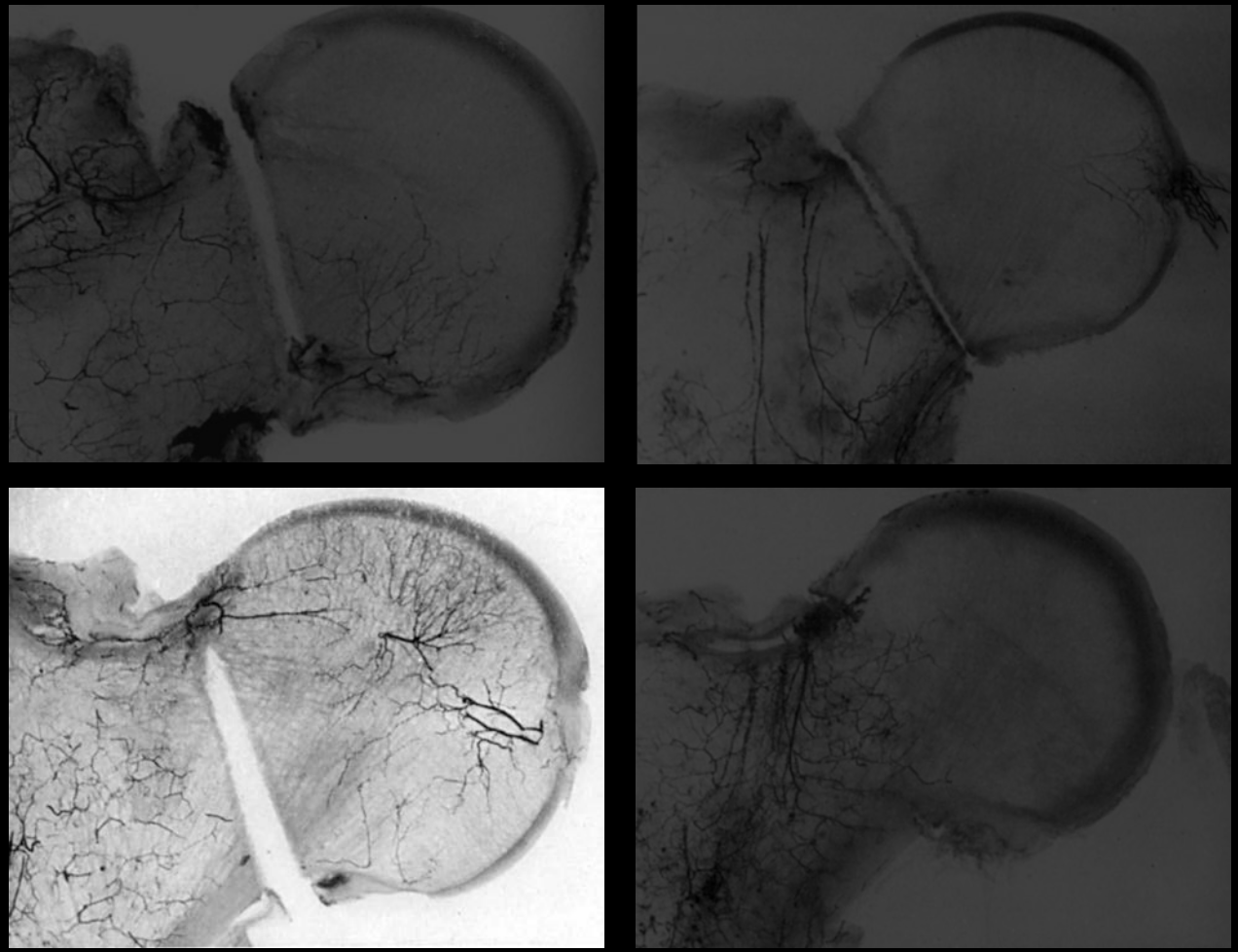

*Sevitt S, Thompson RG. JBJS-B **1965**, 47-B: 560-573*

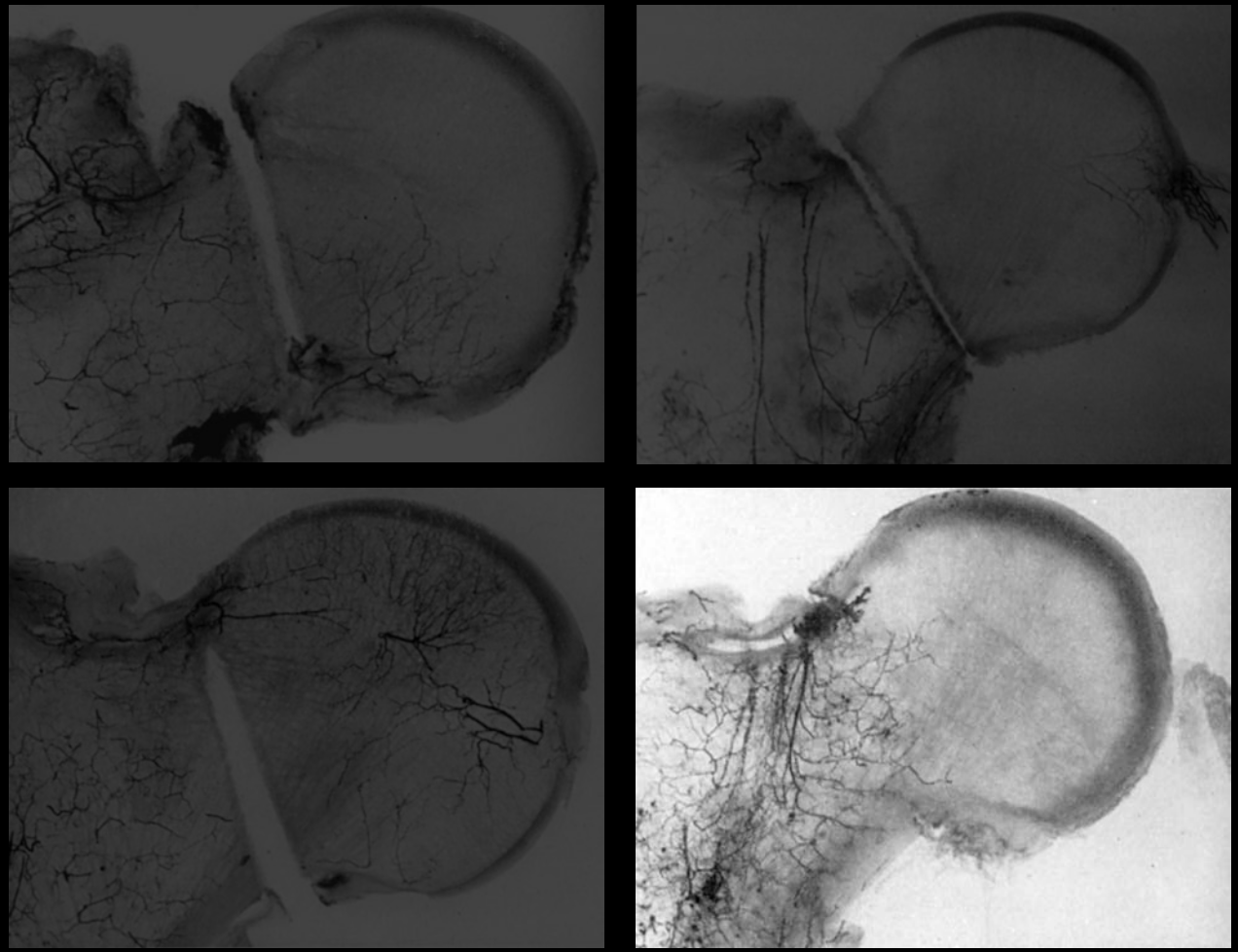

*Sevitt S, Thompson RG. JBJS-B **1965**, 47-B: 560-573*

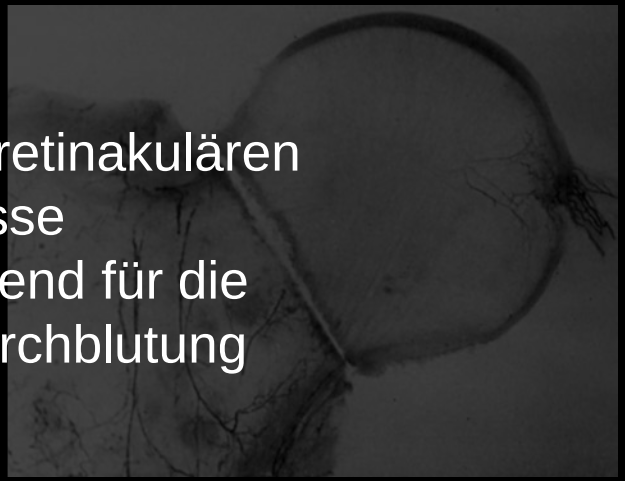

Die superioren retinakulären
Gefässe
sind ausreichend für die
Femurkopfdurchblutung

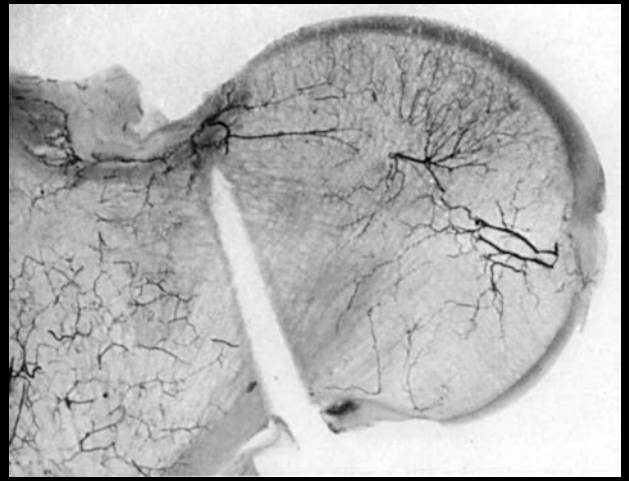

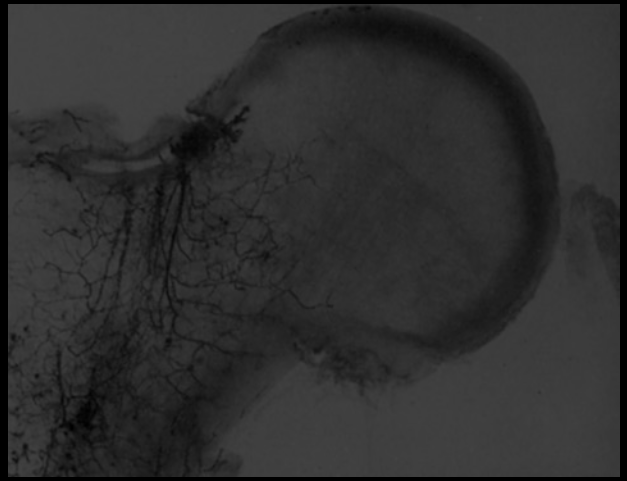

*Sevitt S, Thompson RG. JBJS-B **1965**, 47-B: 560-573*

Intraoperative Objektivierung

*Nötzli et al, JBJS-Br, **2002**;84(2):300-4.*

Relevenz Proximale Femurfrakturen

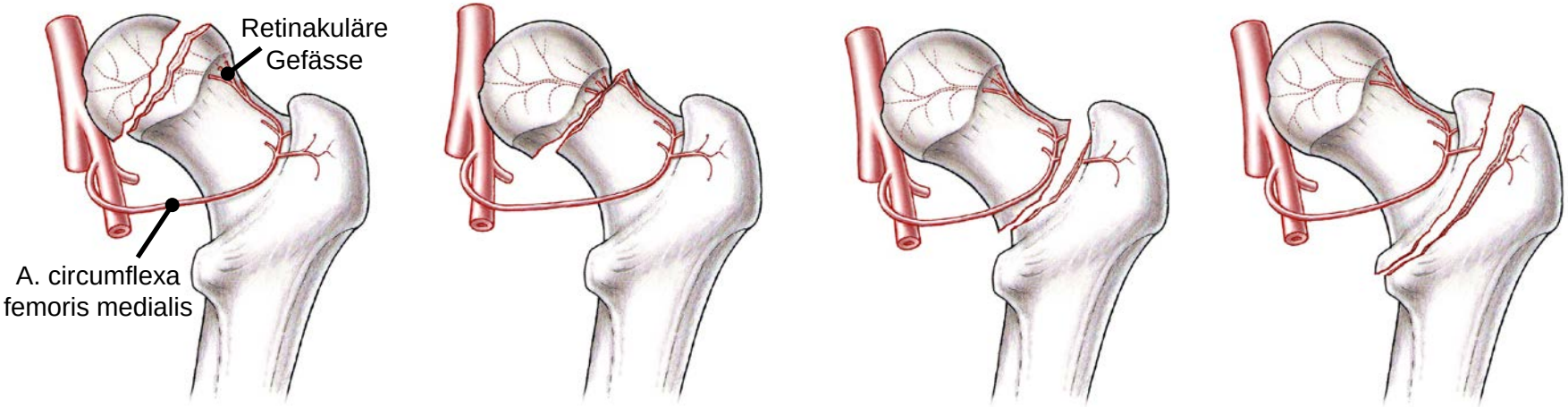

Relevenz Proximale Femurfrakturen

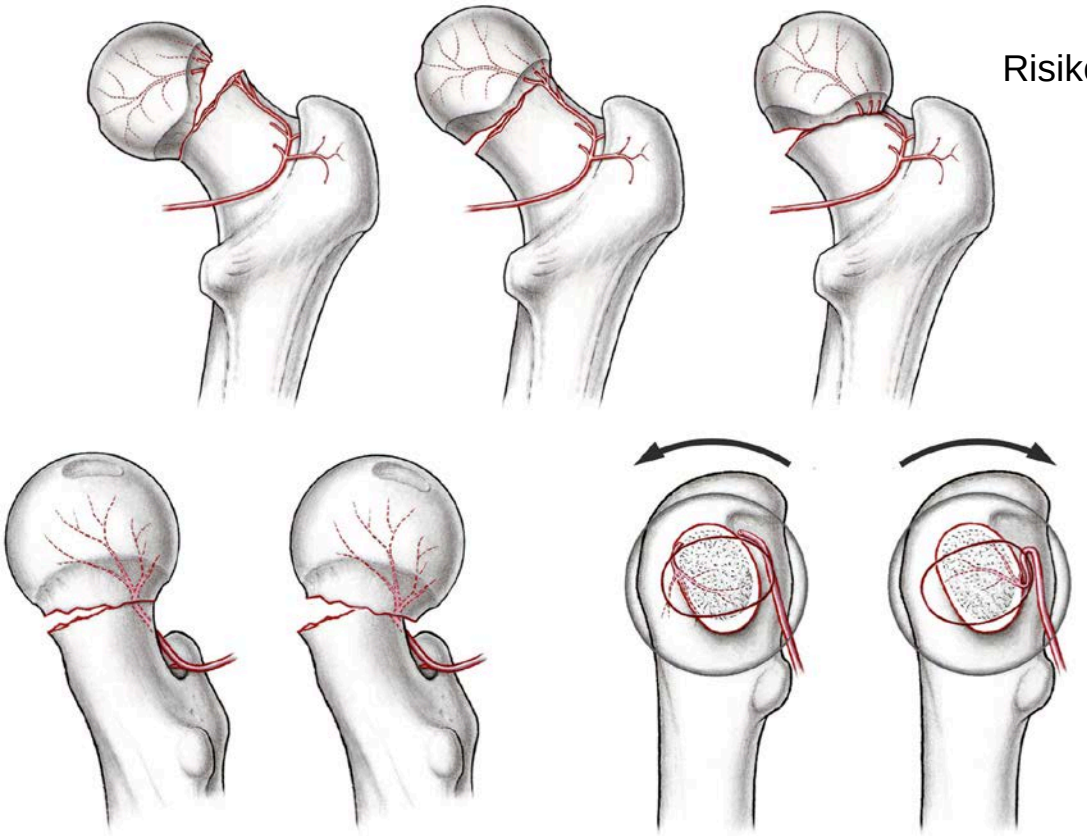

Risiko steigt ab 20°

präoperativ postoperativ 9 Monate

Präoperativ

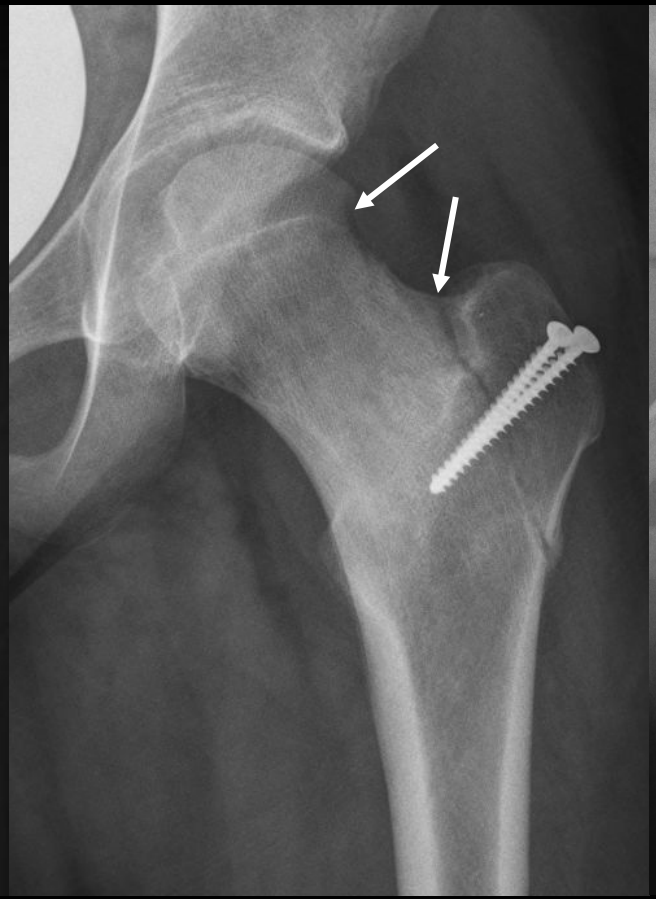

Postoperativ

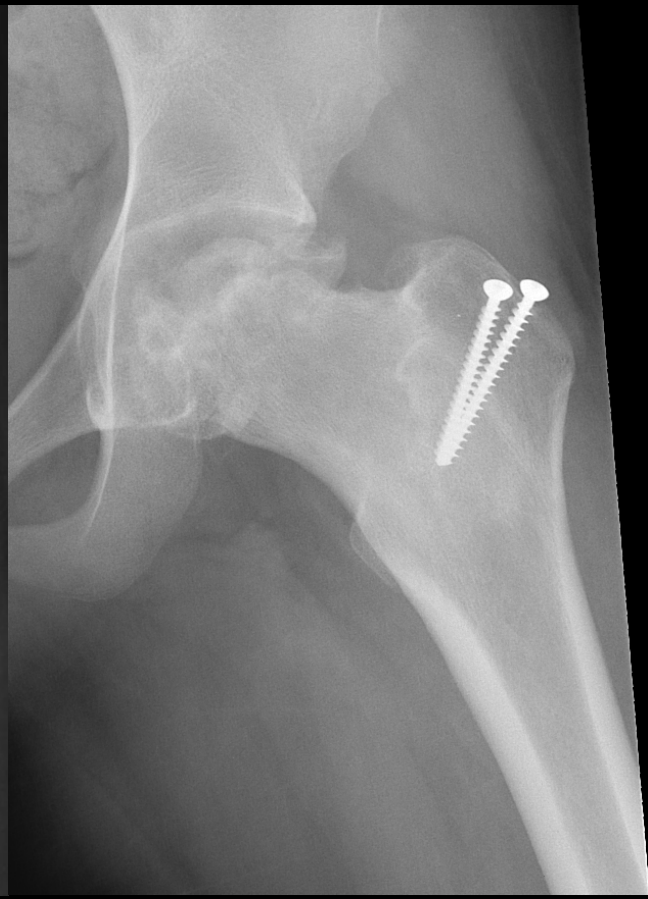

10 Monate

Zusammenfassung

- Der tiefe Ast der **A. circumflexa femoris medialis** liefert die hauptsächliche und relevante Blutzufuhr zur Femurkopfepiphyse

  – Superiores Retinakulum: versorgt die Epiphyse,Hauptgefäss

  – Inferiores Retinakulum: versorgt die Calcarregion und den inferomedialen Aspekt der Epiphyse

- **A. circumflexa femoris lateralis**
  – Anteriores Retinakulum: irrelevant